



Pulmonary artery pressures and right ventricular dimensions of post-COVID-19 patients without previous significant cardiovascular pathology

Kenan Erdem^{a,*}, Ates Duman^b

^a Department of Cardiology, Selcuk University, Faculty of Medicine, Ardiçlı, No:313, 42250 Selçuklu/Konya, Turkey

^b Department of Anesthesiology and Intensive Care, Selcuk University, Faculty of Medicine, Ardiçlı, No:313, 42250 Selçuklu/Konya Konya, Turkey

ARTICLE INFO

Article History:

Received 15 March 2022

Revised 10 August 2022

Accepted 28 August 2022

Available online 30 August 2022

Keywords:

COVID-19

Pulmonary hypertension

Transthoracic echocardiography

ABSTRACT

Background: Pulmonary hypertension is a significant complication of COVID-19, but follow-up data on pulmonary artery pressure after recovery from COVID-19 are limited.

Objectives: To investigate pulmonary artery pressure and heart dimensions in post-COVID-19 patients without a history of significant cardiac pathology.

Methods: Data for 91 eligible adult patients were subjected to 2 analyses. First, patients were grouped according to where they received COVID-19 treatment: the ICU, COVID-19 ward, or outpatient clinic. Second, the severity of COVID-19 was grouped as no pulmonary involvement, non-severe pulmonary involvement, or severe pulmonary involvement based on thoracic computed tomography scores. Heart dimensions were measured and pulmonary artery pressure was estimated using transthoracic echocardiography. The correlation between transthoracic echocardiography findings and COVID-19 severity was assessed.

Results: Pulmonary artery pressure and right-heart dimensions were significantly elevated in the post-COVID-19 patients without a history of risk factors for pulmonary hypertension that presented to the cardiology outpatient clinic with cardiac complaints. Both of these findings were correlated with the severity of COVID-19 and the extent of lung involvement based on thoracic computed tomography.

Conclusion: The present findings confirm that increases in systolic pulmonary artery pressure and right ventricular dimensions persist 2–3 months after recovery from COVID-19 in patients without a history of risk factor for pulmonary hypertension. Furthermore, the increase in pulmonary artery pressure and right ventricular dimensions correlate with the severity of COVID-19 and the extent of lung involvement based on thoracic computed tomography.

© 2022 Elsevier Inc. All rights reserved.

Introduction

Pulmonary hypertension (PH) is a significant complication of coronavirus disease-2019 (COVID-19), which is caused by SARS-CoV-2. Although its true prevalence is unknown, PH is reported in about 15% of hospitalized patients, which negatively affects patient quality of life in the future and is associated with new severe complications.¹ The pathophysiology of PH associated with COVID-19 includes chronic thromboembolism, myocardial involvement, and inflammatory lung disease sequelae associated with direct damage to the vessel wall.^{2–4} Yet, few clinical or follow-up data on long-term

pulmonary artery pressure in post-COVID-19 patients exist.^{2,5} An understanding of the relationship between the radiological and clinical severity of COVID-19, and possible cardiac effects may help cardiologists be more vigilant in cases of COVID-19 patients without a history PH. As such, the present study aimed to use transthoracic echocardiography (TTE) to investigate pulmonary artery pressure and heart dimensions in post-COVID-19 patients without a history of significant cardiac pathology that were referred to our cardiology department for outpatient examination due to cardiac symptoms.

Methods

Study population

This single-center retrospective cohort study included 138 consecutive patients previously treated at our hospital for COVID-19 that were referred to the cardiology department outpatient clinic 2–3 months after recovering from COVID-19 with symptoms of cardiovascular disease between April 2020 and June 2021. The study

Abbreviations: COVID-19, coronavirus disease-2019; ICU, intensive care unit; mPAP, mean pulmonary artery pressure; PH, pulmonary hypertension; RV, right ventricle; sPAP, systolic pulmonary artery pressure; LVEF, left ventricular ejection fraction; TAPSE, tricuspid annular plane systolic excursion; TCT, thoracic computed tomography; TTE, transthoracic echocardiography

* Corresponding author at: Selcuk University, Faculty of Medicine, Department of Cardiology, Ardiçlı, No:313, 42250 Selçuklu, Konya, Turkey.

E-mail address: erdem.kenebr@yahoo.com (K. Erdem).

<https://doi.org/10.1016/j.hrtlng.2022.08.023>

0147-9563/© 2022 Elsevier Inc. All rights reserved.

protocol was approved by the Institutional Ethics Committee (2021/337) and written informed consent was obtained from all patients.

After the COVID-19 pandemic started our large tertiary university hospital was designated as a regional pandemic hospital. The triage of patients that presented with COVID-19 symptoms to the pandemic outpatient clinic was based on the Turkish Ministry of Health Protocol.⁶ Mild cases with flu-like symptoms and oxygen saturation >94% on room air are treated at home on an outpatient basis. In contrast, symptomatic patients with >1 of the following: dyspnea at rest, mental alteration, oxygen saturation <94% on room air, respiratory rate >30 breaths min⁻¹, PaO₂/FiO₂ <300 mmHg, and lung involvement >50% based on thoracic computed tomography (TCT) or additional risk factors were hospitalized. Patients with moderate symptoms that required supplemental oxygen were treated in the COVID-19 ward, and severe cases that required high-flow oxygen or more advanced respiratory support were treated in the ICU.

All the study patients previously had a positive PCR test result during COVID-19 and had returned to daily life after recovery. To evaluate patients without a history of risk factors for PH, patients that had not undergone TCT during COVID-19, patients previously diagnosed with any form of PH, patients with a history of myocardial

infarction, cardiac arrhythmia, and heart failure leading to PH, patients with chronic respiratory diseases, and those with a history of pulmonary thromboembolism that could cause PH were excluded. In addition, patients treated with vasodilators for PH were excluded. TCT images recorded during COVID-19 were obtained from the hospital's electronic database. Routine cardiac evaluation, 12-lead electrocardiography, and TTE were conducted upon referral to the outpatient clinic. The severity of COVID-19 and patient grouping were based on where they were treated, as follows: outpatient (mild); COVID-19 ward (moderate); ICU (severe).

Transthoracic echocardiography

TTE was performed by a cardiologist with ultrasonography experience using a dedicated ultrasound machine (Vivid E9, GE Vingmead, Horten, Norway) with an M5S cardiac sector probe (1.5–4.5 MHz), according to the American Society of Echocardiography recommendations for transthoracic studies.⁷ In all, 3 consecutive cycles were averaged for every parameter. Echocardiographic data were stored in an electronic database. Left atrium dimension, and left ventricle end-systolic and end-diastolic diameters were measured. The left ventricular

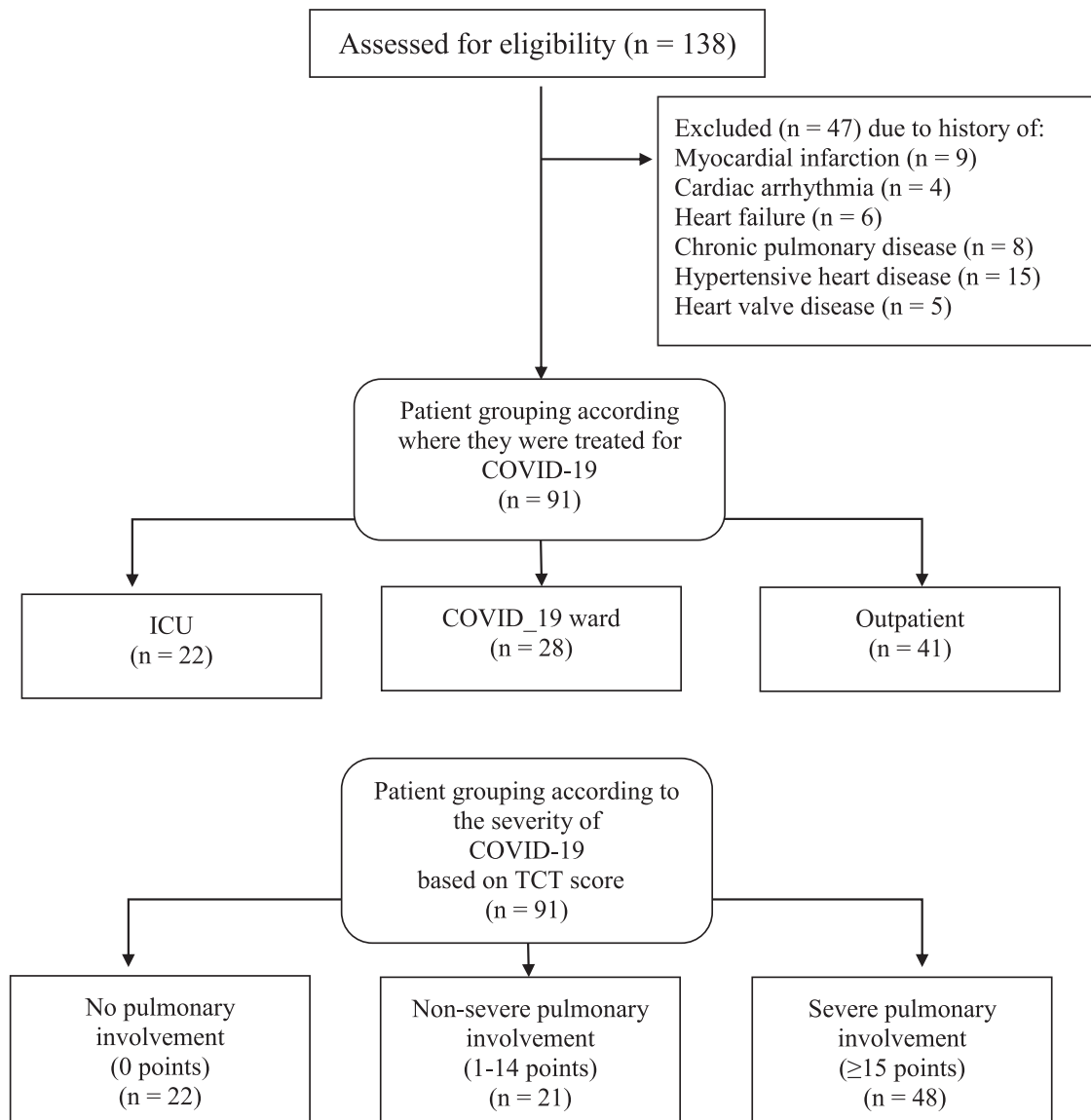


Fig. 1. Patient enrollment.

ejection fraction (LVEF) was estimated via the modified Simpson's rule. Right ventricle (RV) chamber size, including basal and midventricular dimensions and length, was measured. RV dimensions were measured using the apical end-diastolic 4-chamber view. RV dilatation (RVD) criteria were determined according to Lang et al.⁸ Right atrial pressure was estimated and scored as 5, 10, 15, or 20 mm Hg based on inferior vena cava diameter and distensibility, and pulsed-wave Doppler measurement of hepatic vein flow. None of the patients had echocardiographic evidence of pulmonary stenosis or RV outflow tract obstruction. Systolic pulmonary artery pressure (sPAP) was estimated using the following formula: $SPAP = 4 \times \text{tricuspid regurgitation peak velocity}^2 + \text{right atrial pressure}$.

Mean pulmonary artery pressure (mPAP) was calculated as the acceleration time of the pulmonary artery velocity (Pact) using the Mahan formula⁹: $[mPAP \text{ (mmHg)} = 79 - (0.62 \times \text{Pact (ms)}]$.

PH was defined as resting sPAP >35 mmHg and mPAP >25 mmHg.^{10,11} Tricuspid annular plane systolic excursion (TAPSE) was recorded using cross-sectional-guided M-mode at the RV free wall; however, S' wave right lateral annulus based on tissue Doppler, RV FAC (RV fractional area change), and right atrium measurements were not recorded because they were not routinely evaluated in our outpatient TTE practice, except for patients with significantly high PAP and severe RVD. In addition, none of the patients underwent RV catheterization.

Radiographic assessment

An experienced radiologist assessed pulmonary lesions in TCT images using a simplified severity score based on Pan et al.,¹² which takes into account the extent of ground-glass opacity in each of the 5 lobes (0: involvement; 1: <5% involvement; 2: 5%-25% involvement; 3: 26%-50% involvement; 4: 51%-75% involvement; 5: >75% involvement). The total TCT score was the sum of the individual lobar scores and ranged from 0 (no involvement) to 25 (maximum involvement). The patients were then classified according to the compromised lung values (COVID-19 severity): subgroup 1: no pulmonary involvement (0 points); subgroup 2: non-severe pulmonary involvement (1-14 points); subgroup 3: severe pulmonary involvement (>15 points).¹²

Statistical analysis

Prior to analysis the patients were grouped according to 2 criteria. First, the patients were grouped according to where they were treated for COVID-19, as follows: ICU: n = 22; COVID-19 ward: n = 28; outpatient clinic: n = 41. Second, the patients were grouped according to ground-glass opacity in TCT images, as follows: no pulmonary involvement: n = 22; non-severe pulmonary involvement: n = 21; severe pulmonary involvement: n = 48.

Data were analyzed using IBM SPSS Statistics for Windows v.21.0 (IBM Corp., Armonk, NY). Data are shown as number, percentage, and mean \pm SD. The chi-square test was used to compare the frequency distribution of categorical data between groups. The Kolmogorov-Smirnov test, or Shapiro-Wilk test, and skewness and Kurtosis values were used to determine the normality of the distribution of numerical data. The ANOVA test and Tukey's post-hoc test were used to compare numerical data between >2 groups. The level of statistical significance was set at $P < 0.05$.

Results

The study included 138 consecutive post-COVID-19 patients that underwent TTE, but only 91 patients were included in the analysis, as 47 were excluded due to a history of risk factors for PH (Fig. 1). Baseline clinical characteristics are shown in Table 1. The median patient age was 49.00 years (IQR: 63.5-40.5 years), and 50.5% of the patients were female. The median time from COVID-19 recovery to outpatient clinic referral was 67.00 d (IQR: 76-56 d).

Clinical features

Presenting symptoms

The most common presenting symptom was exertional dyspnea (52.7%), followed by palpitations (48.3%), chest pain (31.8%), and dyspnea at rest (15.3%). Some patients had ≥ 2 symptoms (Table 1).

Table 1
Patient demographics, risk factors, presenting symptoms, and laboratory findings.

	ICU(n = 22)	COVID-19 Ward(n = 28)	Outpatient(n = 41)	P
Demographics				
Mean age, years	56.72 \pm 15.71	52.78 \pm 16.04	47.89 \pm 11.71	0.063
Male, n	13 (59%)	14 (50%)	18 (43.9%)	0.515
Mean BMI, kg m ⁻²	28.13 \pm 3.25	28.59 \pm 4.94	28.33 \pm 3.26	0.915
History of Risk Factors				
Hypertension, n	7 (31.81%)	6 (21.42%)	7 (17.07%)	0.402
Diabetes Mellitus, n	6 (27.27%)	3 (10.71%)	4 (9.75%)	
Current Smoker, n	4 (18.18%)	3 (10.71%)	6 (14.63%)	0.753
Coronary Artery, n Disease, n	0	0	0	NA
Presenting Symptoms				
Exertional Dyspnea, n	22 (100%)	20 (71.4%)	7 (17.1%)	ICU vs. Outpatient P < 0.001 ICU vs. COVID-19 Ward P = 0.006
Chest Pain, n	13 (43.3%)	9 (30.0%)	8 (26.7%)	ICU vs. Outpatient P = 0.001
Palpitations, n	12 (26.7%)	14 (31.1%)	19 (42.2%)	0.823
Dyspnea at Rest, n	9 (40.9%)	3 (10.7%)	2 (4.9%)	ICU vs. Outpatient P < 0.001 ICU vs. COVID-19 Ward P = 0.013
Back Pain, n	18 (81.8%)	20 (71.4%)	16 (39.0%)	ICU vs. Outpatient P = 0.001
Laboratory Findings				
Mean D-dimer, ng/mL	293.40 \pm 161.51	221.50 \pm 127.75	238.48 \pm 126.81	P = 0.064
Mean troponin, ng/L	3.98 \pm 2.77	4.57 \pm 4.32	4.61 \pm 3.22	P = 0.804

Patients with coronary artery disease were excluded.

TTE measurements

PH was observed in 15 patients (16.4%). Both sPAP and mPAP were elevated in 10 of the 15 patients, and sPAP elevation only was observed in 5 patients, whereas mild RVD was observed in 16 patients (17.5%). In all, 13 patients (14.2%) had both PH and RVD.

TTE findings according to where patients were treated for COVID-19 are presented in Table 2. sPAP and mPAP in the ICU patients were significantly higher than in the COVID-19 ward patients and outpatients ($P < 0.001$). Moreover, sPAP and mPAP were significantly higher in the patients treated in the COVID-19 ward than in the outpatients ($P < 0.001$). RV dimensions, basal diameter, mid diameter, and longitudinal dimensions were significantly larger in the ICU patients than in those treated in the COVID-19 ward ($P < 0.05$) and the outpatients ($P < 0.001$). RV dimensions were also significantly larger in the COVID-19 ward patients than in the outpatients ($P < 0.001$). TAPSE was shorter in the ICU patients than in the outpatients ($P = 0.010$). The LVEF did not differ significantly according to where the patients were treated for COVID-19.

A comparison of TTE and TCT findings is shown Table 3. sPAP and mPAP in the patients with severe pulmonary involvement were significantly higher than in the patients with non-severe involvement and no involvement ($P < 0.001$). RV dimensions, basal diameter, mid diameter, and longitudinal dimensions were significantly larger in the patients with severe pulmonary involvement, as compared to those with non-severe involvement and no involvement ($P < 0.001$). RV mid diameter was also significantly larger in the patients with non-severe pulmonary involvement ($P < 0.021$). TAPSE was significantly shorter in patients with severe pulmonary involvement than in those with no involvement. ($P < 0.05$). The LVEF did not differ significantly according to the degree of pulmonary involvement.

Discussion

The present study observed significant increases in PAP and right-heart dimensions in adult post-COVID-19 patients without a history of risk factors for PH that presented to the cardiology outpatient clinic with cardiac complaints. These increases were correlated with the severity of COVID-19 and the extent of pulmonary involvement based on TCT. The present findings suggest that significant increases in sPAP 2-3 months after recovery from COVID-19 can occur even in low-risk patients that present for cardiac assessment.

The primary characteristic of COVID-19 is prominent pulmonary involvement.¹³ Whereas in most COVID-19 cases symptoms are mild, including fever, cough, and flu-like symptoms, the disease can lead to

Table 2
TTE findings according to where patients were treated for COVID-19.

	ICU (n = 22)	COVID-19 Ward	
(n = 28)	Outpatient		
(n = 41)			
sPAP, mmHg	35.63 ± 8.02*†	28.03 ± 4.29*	19.80 ± 4.26
mPAP, mmHg	23.45 ± 4.97*†	18.75 ± 3.18*	13.65 ± 2.84
RV basal diameter, mm	32.38 ± 2.51*†	30.28 ± 3.33*	26.53 ± 2.94
RV mid diameter, mm	33.14 ± 1.95*†	30.00 ± 3.10*	27.19 ± 3.15
RV longitudinal dimension, mm	77.33 ± 5.52*†	73.35 ± 6.39*	66.63 ± 5.11
TAPSE, mm	18.84 ± 3.02*	19.80 ± 2.31	20.73 ± 1.65
LVEF, %	60.04 ± 3.89	59.88 ± 2.84	60.75 ± 3.08
Left atrium diameter, mm	38.18 ± 2.19	37.03 ± 3.86	36.00 ± 3.54
LVESD, mm	30.40 ± 3.27	30.46 ± 3.37	30.43 ± 4.38
LVEDD, mm	48.90 ± 3.61	48.67 ± 3.55	47.48 ± 3.86

Data are presented as mean ± SD. sPAP: systolic pulmonary artery pressure; mPAP: mean pulmonary artery pressure; RV: right ventricle; LV: left ventricle; LVEF: left ventricular ejection fraction; LVESD: LV end-systolic diameter; LVEDD: LV end-diastolic diameter; TAPSE: tricuspid annular plane systolic excursion.

* $P < 0.001$ vs. outpatient.

† $P < 0.001$ vs. COVID-19 ward.

Table 3
Comparison of TTE and TCT findings.

	*Severe involvement		
(n = 48)	*Non-severe involvement		
(n = 21)	*No involvement		
(n = 22)			
sPAP, mmHg	31.89 ± 6.98*#	21.10 ± 4.68	17.90 ± 2.09
mPAP, mmHg	21.23 ± 4.33*#	14.15 ± 3.27	12.50 ± 1.50
RV basal diameter, mm	31.52 ± 2.93*#	27.84 ± 2.85	25.59 ± 2.53
RV mid diameter, mm	31.63 ± 2.76*#	28.52 ± 2.91†	25.86 ± 3.22
RV longitudinal dimension, mm	75.91 ± 5.70*#	66.05 ± 4.61	65.72 ± 4.75
TAPSE, mm	19.31 ± 2.62†	20.47 ± 2.26	21.05 ± 1.27
LVEF, %	59.77 ± 3.22	60.73 ± 3.73	61.31 ± 2.66
Left atrium diameter, mm	37.76 ± 3.19	36.84 ± 3.00	34.81 ± 3.86
LVESD, mm	30.95 ± 3.32	31.05 ± 5.32	28.81 ± 2.95
LVEDD, mm	49.17 ± 3.29	47.42 ± 4.54	46.77 ± 3.49

Data are presented as mean ± SD. sPAP: systolic pulmonary artery pressure; mPAP: mean pulmonary artery pressure; RV: right ventricle; LV: left ventricle; LVEF: left ventricular ejection fraction; LVESD: LV end-systolic diameter; LVEDD: LV end-diastolic diameter; TAPSE: tricuspid annular plane systolic excursion.*Based on TCT severity score.⁹

* $P < 0.001$ vs. non-severe involvement.

$P < 0.001$ vs. no-involvement.

† $P < 0.05$ vs. no-involvement.

the development of pneumonia.¹⁴ Among patients with severe COVID-19 pneumonia, ~40% develop ARDS and 20% of such ARDS cases are severe. Among these patients that recover, >33% are expected to develop long-term fibrotic abnormalities.^{15,16} Hypoxic pulmonary vasoconstriction, high airway pressure mechanical ventilation, and thrombotic events can all contribute to endothelial and alveolar injury, resulting in fibrosis.¹⁷ Fibrotic changes in the lungs and other factors are most commonly responsible for the development of PH during the course of COVID-19.¹⁸ Even in mild and moderate COVID-19 patients lung edema, inflammatory infiltrates, and thickening of the alveolar septa can lead to parenchymal damage, resulting in altered pulmonary hemodynamics, which then leads to an increase in PAP and RV involvement.¹

The prevalence of PH in critically ill COVID-19 patients with ARDS and respiratory failure is significant.¹ Considering that most patients suffer from mild-moderate COVID-19 and are treated in wards or at home, the incidence of PH in such patients is not precisely known. Earlier TTE studies primarily assessed COVID-19 patients with severe pneumonia or ARDS.^{19–21} Earlier studies on post-COVID-19 patients generally followed-up all patients, including patients with a history of or risk for PH.^{2,5} The present study differs significantly in that it excluded patients with a history of risk factors for pH and patients with known comorbidities that can lead to an increase in PAP. In addition, the present study included only post-COVID-19 patients that presented to the cardiology outpatient clinic with cardiac complaints, with the aim of determining the incidence of PH (which is expected to decrease gradually after recovery from COVID-19) in such patients and to determine if there is a relationship between the severity of COVID-19 and increased PAP.

Pagenesi et al.¹ observed that the prevalence of PH among ICU and non-ICU hospitalized COVID-19 patients was 12%. The prevalence of PH during hospitalization is assumed to decrease after recovery from COVID.² The present findings were observed in post-COVID-19 patients; therefore, it may be expected that the observed increases in PAP will gradually decrease and that the incidence of PH in the patients will be lower than in hospitalized COVID-19 patients. Interestingly, the prevalence of PH in the present study was 10.9%, which is close to that reported by Pagenesi et al.¹ Furthermore, in the

present study sPAP increased as the severity of COVID-19 or the TCT score increased.

COVID-19 pneumonia affects both the left and right ventricles of the heart.^{19–21} During hospitalization the most common cardiac manifestation during the acute phase of COVID-19 is RV dilatation/dysfunction.²¹ Assessment of RV function in hospitalized COVID-19 patients is an independent predictor of 60-d mortality and can be used to identify patients with a high risk of poor outcome.^{17,19} COVID-19 is also associated with other cardiac complications, including myocarditis, acute myocardial infarction, heart failure, and central and peripheral thromboembolic events.²² Myocardial injury occurs in ~20%–30% of hospitalized COVID-19 patients^{22,23}; therefore, we think myocardial injury resulting from COVID-19 infection may be the primary reason post-COVID-19 patients without a history of cardiac disease present to our cardiology outpatient clinic with cardiac symptoms.

The present study has a few limitations, including its retrospective design. Moreover, the study population was small due to limiting the study to patients that recovered from COVID-19 and had a negative history of risk factors for PH. Additionally, baseline TTE values for the patients were not obtained and there was no control group. Because this was not a prospective echocardiographic study the data are limited to the routine echocardiography criteria recorded during patient evaluation in our outpatient clinic; therefore, heart diameters and ventricular functions were not recorded in all the patients. Another limitation is that the TTE assessments were not validated via invasive RV catheterization. Finally, the presented data represent the findings obtained 2–3 months post-COVID-19 and longer-term follow-up may be required to more clearly determine if the observed increase in sPAP persists over time.

Conclusion

The present findings show that 2–3 months after recovering from COVID-19 sPAP and RV dimensions are increased in patients without a history of risk factors for PH. Furthermore, the increases in PAP and RV dimensions correlate with the severity of COVID-19 and the extent of pulmonary involvement based on TCT. Based on these findings, we think it is necessary for cardiologists to consider PH in post-COVID patients, and to carefully review the radiological and clinical findings in patients with cardiac complaints that present after recovery from COVID-19.

Funding Statement

This study did not receive any financial support.

Ethics Statement

The study protocol was approved by the of Selçuk University School of Medicine Institutional Review Board (2021/337) and was conducted in accordance with the Declaration of Helsinki Declaration. All the participants provided written informed consent.

Declaration of Competing Interest

The authors declare there are no conflicts of interest financial or otherwise related to the material presented herein.

Acknowledgments

The authors thank Associate Professor Alaeddin Nayman for assessing the pulmonary lesions imaged via TCT.

References

- Pagnesi M, Baldetti L, Beneduce A, et al. Pulmonary hypertension and right ventricular involvement in hospitalised patients with COVID-19. *Heart*. 2020;106(17):1324–1331. <https://doi.org/10.1136/heartjnl-2020-317355>.
- Tudoran C, Tudoran M, Lazureanu VE, et al. Evidence of pulmonary hypertension after SARS-CoV-2 infection in subjects without previous significant cardiovascular pathology. *J Clin Med*. 2021;10(2):199. <https://doi.org/10.3390/jcm10020199>.
- Magro C, Mulvey JJ, Berlin D, et al. Complement associated microvascular injury and thrombosis in the pathogenesis of severe COVID-19 infection: a report of five cases. *Transl Res*. 2020;220(6):1–13. <https://doi.org/10.1016/j.trsl.2020.04.007>.
- Cueto-Robledo G, Porres-Aguilar M, Puebla-Aldama D, et al. Severe pulmonary hypertension: an important sequel after severe post-acute COVID-19 pneumonia. *Curr Probl Cardiol*. 2022;47(3). <https://doi.org/10.1016/j.cpcardiol.2021>.
- Tudoran C, Tudoran M, Lazureanu VE, et al. Factors influencing the evolution of pulmonary hypertension in previously healthy subjects recovering from a SARS-CoV-2 infection. *J Clin Med*. 2021;10(22). <https://doi.org/10.3390/jcm10225272>.
- <https://covid19.saglik.gov.tr/Eklenti/42169/0/covid-19rehberieriskinhastayonetimivtedavi20122021v6pdf.pdf>. 2022.
- Mitchell C, Rahko PS, Blauwet LA, et al. Guidelines for performing a comprehensive transthoracic echocardiographic examination in adults: recommendations from the American society of echocardiography. *J Am Soc Echocardiogr*. 2019;32(1):1–64. <https://doi.org/10.1016/j.echo.2018.06.004>.
- Lang RM, Bierig M, Devereux RB, et al. Recommendations for chamber quantification. *Eur J Echocardiogr*. 2006;7(2):79–108. <https://doi.org/10.1016/j.euje.2005.12.01>.
- Dabestani A, Mahan G, Gardin JM, et al. Evaluation of pulmonary artery pressure and resistance by pulsed Doppler echocardiography. *Am J Cardiol*. 1987;59(6):662–668. [https://doi.org/10.1016/0002-9149\(87\)91189-1](https://doi.org/10.1016/0002-9149(87)91189-1).
- Bosson E, D'Andrea A, D'Alto M, et al. Echocardiography in pulmonary arterial hypertension: from diagnosis to prognosis. *J Am Soc Echocardiogr*. 2013;26(1):1–14. <https://doi.org/10.1016/j.echo.2012.10.009>.
- Galiè N, Humbert M, Vachiery JL, et al. 2015 ESC/ERS guidelines for the diagnosis and treatment of pulmonary hypertension: the joint task force for the diagnosis and treatment of pulmonary hypertension of the European society of cardiology (ESC) and the European respiratory society (ERS); endorsed by: association for European paediatric and congenital cardiology (AEPC), international society for heart and lung transplantation (ISHLT). *Eur Heart J*. 2016;37(1):67–119. <https://doi.org/10.1093/eurheartj/ehv317>.
- Pan F, Ye T, Sun P, et al. Time course of lung changes at chest ct during recovery from coronavirus disease 2019 (COVID-19). *Radiology*. 2020;295(3):715–721. <https://doi.org/10.1148/radiol.202003070>.
- Guan WJ, Ni ZY, Hu Y, et al. China medical treatment expert group for covid-19. Clinical characteristics of coronavirus disease 2019 in China. *N Engl J Med*. 2020;382(18):1708–1720. <https://doi.org/10.1056/NEJMoa2002032>.
- Rodriguez-Morales AJ, Cardona-Ospina JA, Gutiérrez-Ocampo E, et al. Clinical, laboratory and imaging features of COVID-19: a systematic review and meta-analysis. *Travel Med Infect Dis*. 2020;34(101623). <https://doi.org/10.1016/j.tmaid.2020.101623>. <https://www.lancocovid.org>.
- Wu C, Chen X, Cai Y, et al. Risk factors associated with acute respiratory distress syndrome and death in patients with coronavirus disease 2019 pneumonia in wuhan, china. *JAMA Intern Med*. 2020;180(7):934–943. <https://doi.org/10.1001/jamainternmed.2020.0994>.
- Vasarmidi E, Tsitoura E, Spandidos DA, et al. Pulmonary fibrosis in the aftermath of the COVID-19 era. *Exp Ther Med*. 2020;20(3):2557–2560. <https://doi.org/10.3892/etm.2020.8980>.
- Díaz JJS, Rincon JM, López MAR, et al. Echocardiographic 60-day mortality markers in patients hospitalized in intensive care for COVID-19. *Heart Lung*. 2022;3(52):123–129. <https://doi.org/10.1016/j.hrtlng.2021.12.007>.
- Tale S, Ghosh S, Meitei SP, et al. Post-COVID-19 pneumonia pulmonary fibrosis. *QJM*. 2020;113(11):837–838. <https://doi.org/10.1093/qjmed/hcaa255>.
- Li Y, Li H, Zhu S, et al. Prognostic value of right ventricular longitudinal strain in patients with COVID-19. *JACC Cardiovasc Imaging*. 2020;13(11):2287–2299. <https://doi.org/10.1016/j.jcmg.2020.04.014>.
- Park JF, Banerjee S, Umar S. In the eye of the storm: the right ventricle in COVID-19. *Pulm Circ*. 2020;10(3). <https://doi.org/10.1177/2045894020936660>. 2045894020936660.
- Szekely Y, Lichter Y, Taieb P, et al. Spectrum of cardiac manifestations in COVID-19: a systematic echocardiographic study. *Circulation*. 2020;142(4):342–353. <https://doi.org/10.1161/CIRCULATIONAHA.120.047971>.
- Guo T, Fan Y, Chen M, et al. Cardiovascular implications of fatal outcomes of patients with coronavirus disease 2019 (COVID-19). *JAMA Cardiol*. 2020;5(7):811–818. <https://doi.org/10.1001/jamacardio.2020.1017>.
- Shi S, Qin M, Shen B, et al. Association of cardiac injury with mortality in hospitalized patients with COVID-19 in Wuhan, China. *JAMA Cardiol*. 2020;5(7):802–810. <https://doi.org/10.1001/jamacardio.2020.0950>.